

# The Galaxy Experience: **First 75 Cases**

---

Amit Mahajan, MD

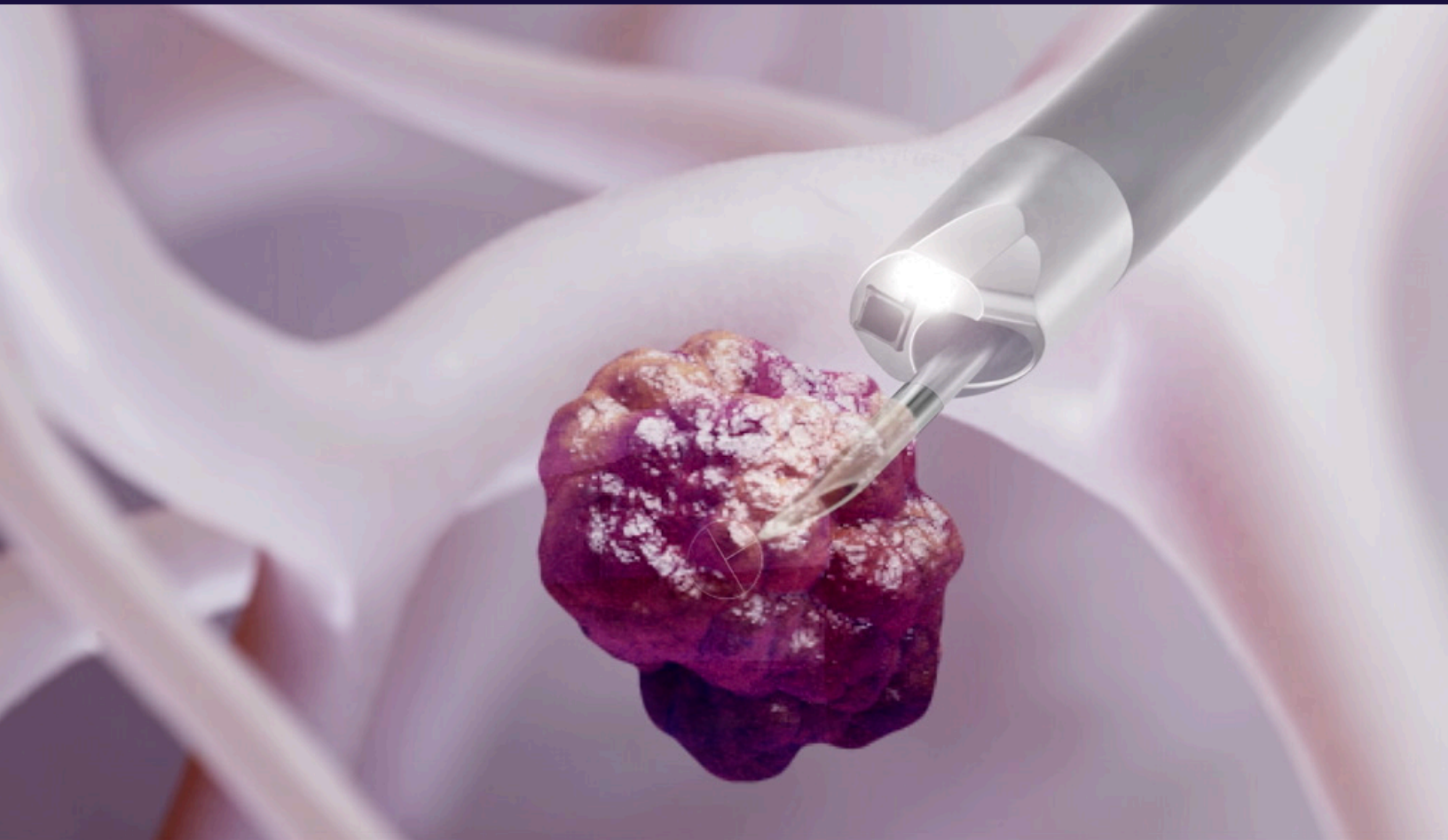



**Amit Mahajan, MD**

Medical Director of Interventional Pulmonology, Inova Fairfax Hospital

Dr. Mahajan is one of the earliest Galaxy System™ users in the United States. He oversees Inova's incidental lung nodule program and lung cancer screening program. As a leader in interventional pulmonology, he is critical of data when considering robotics, and whether they can increase his technique and diagnostic yield. He has been involved in numerous studies, including BENEFIT, NAVIGATE and MATCH.



*"My ultimate goal is to be able to perform bronchoscopic biopsies of lung nodules in the periphery with laser accuracy. The challenges created by CT-to-body divergence have plagued interventional pulmonology for decades. The ability to see lesions clearly with advanced imaging is important not just to obtain diagnoses, but also to confirm true negatives."*

— Amit Mahajan, MD

# Over 300 navigational bronchoscopies annually

Prior to the Galaxy System™, I've used the ILLUMISITE™ Fluoroscopic Navigation Platform and Olympus bronchoscopes. Some of the challenges I've encountered with these technologies include:

- Poor image quality
- Lack of bronchoscope stability
- CT-to-body divergence

I've started using the Galaxy System as I believe its integrated imaging capability could help correct for CT-to-body divergence, while its robotic arm can provide stability with access to peripherally located lesions, thus helping improve diagnostic yields.

We aim to be as financially sustainable as possible in performing our bronchoscopic procedures. We hope to minimize direct costs while still providing the highest level of care for our patients. While a positive contribution margin is essential for program growth, we understand that use of the Galaxy System offers the highest level of technology for diagnosing cancer early.

We are also able to rely on an increased rate of diagnosis for referrals to thoracic surgery for resection.

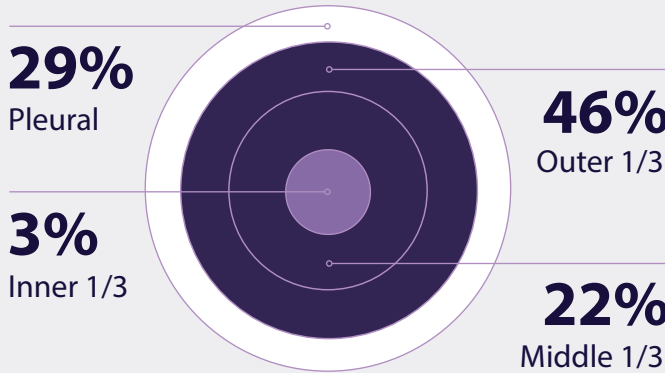


# Insights from **the first 75** **Galaxy System™** procedures

80 lesions investigated in 75 patients.

LESION CHARACTERISTICS	PROCEDURE RESULTS
<b>14mm</b> average size	<b>44 mins</b> Average procedure time (Scope in – Scope out)
<b>88%</b> were less than/equal to 20mm	
<b>37%</b> were less than/equal to 10mm	<b>100%*</b> CT-to-body divergence observed
<b>9%</b> were GGOs	
<b>89%</b> had no bronchus sign	<b>92%*</b> Tool-in-Lesion Confirmed

LESION LOCATION	Right	Left
Upper	38%	25%
Middle	4%	—
Lower	16%	17%



**Challenging lesions in challenging locations**  
Most lesions were in upper lobes, and outer 1/3

**96%**  
Diagnostic Yield

\* Results assessed from observations recorded in 62 procedures; Observations for 13 procedures were not recorded

# Case example

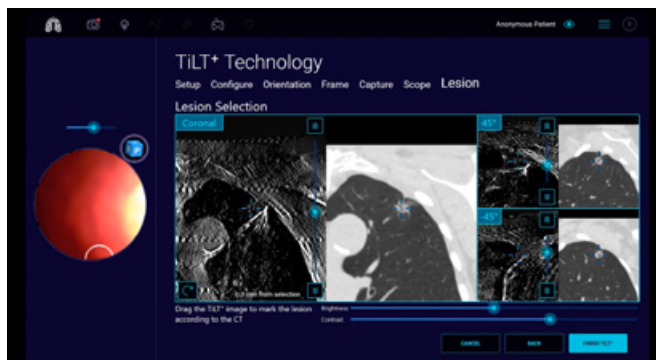
Performed in December, 2023

## Presentation:

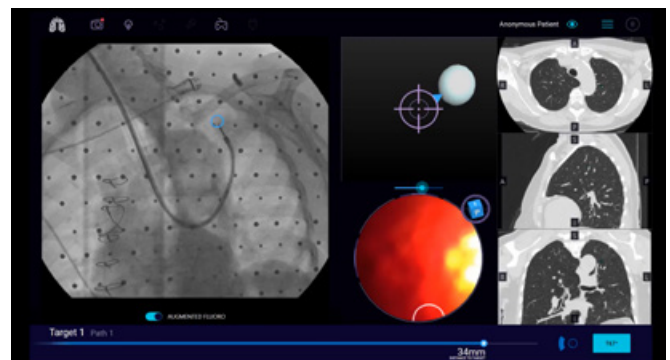
- Female patient with 9mm nodule in the left upper lobe (LUL), located peripherally close to the pleura, approached me for a second opinion. Her initial consult informed her that the only way to biopsy the peripherally located small nodule would be through surgery.
- Patient was reluctant to undergo surgery without knowing that the lesion was malignant.
- The lesion had no bronchus sign, and had Ground-glass opacity (GGO) on CT imaging.
- Reviewed CT scan and discussed biopsy procedure via telemedicine visit, as patient was located more than 2 hours away.

## Approach:

- Galaxy System's EMN guidance helped navigate to the lesion. Upon approaching the lesion, a tomosynthesis image was generated.
- Tomosynthesis view indicated that there was CT-to-body divergence, requiring updating the lesion location and adjusting the position of the scope tip.
- After deploying the needle, a second tomosynthesis image showed that the tool was not in the lesion. Micro-adjustments were made and tool-in-lesion was confirmed.



Tool not in lesion



Tool-in-lesion

- Once tool-in-lesion was confirmed, biopsy was performed without any difficulty.

## Outcome:

- Patient was diagnosed with adenocarcinoma in the left upper lobe. No procedure complications were reported. A fiducial was placed as the patient was a candidate for SBRT of this early-stage cancer.

For more information, please visit **noahmed.com**

© 2024 by Noah Medical. All rights reserved. ML-053 Rev. B

